

OUTCOME OF VISUAL ACUITY REHABILITATION OF LOW VISION IN CHILDREN AFTER CONGENITAL CATARACT SURGERY: A CASE SERIES

Nanda W. Anandita, Lely Retno Wulandari

Ophthalmology Department, Faculty of Medicine, Universitas Brawijaya, Indonesia
Email: nan_anandita@yahoo.com, lelyretnowulandari@gmail.com

Abstract

Congenital cataract is the major cause of treatable visual impairment in children. The first 6 weeks of children's age is the critical period for visual experience. Based on this, it is suggested that surgery in congenital cataract cases should be performed as soon as possible. The visual outcome after cataract surgery depends on the surgeon, the age of the children, and other visual conditions. Management of the visual rehabilitation in this case is very challenging. Most of the problem after congenital cataract surgery is amblyopia. The purpose of this paper is to report the visual acuity outcome after visual rehabilitation of children who had been performed cataract surgery. This case is a case series of the visual acuity outcome of children who had been performed bilateral cataract congenital surgery in dr Syaiful Anwar Hospital, Malang, Indonesia . The data was obtained from medical record and we compared the visual acuity before and after visual rehabilitation and the outcome based on their timing when they were performed the surgery and the visual acuity correction was obtained. There were 5 cases; 4 cases was bilateral aphakia because of microcornea and 1 case was bilateral pseudophakia with high myopia. Their ages ranged from 20 months – 12 year old. Most of the children got spectacle for their visual acuity rehabilitation and the power of spectacle lens was based on streak retinoscopy. The aphakia and pseudophakia children obtained better visual acuity after visual rehabilitation. The younger the age in which they underwent surgery and the earlier they got visual correction after cataract surgery the better their visual acuity outcome will be. The success of visual rehabilitation depends on ocular condition, age, the visual rehabilitation technique and the compliance of the patients and the parents.

Keywords: Amblyopia, Aphakia, Congenital Cataract, Low Vision, Visual Rehabilitation, Pseudophakia.

INTRODUCTION

Congenital cataract is the major cause of preventable blindness in children in the wide world (Giles et al., 2016); (Chak et al., 2006). The critical period of the

visual experience and the timing of surgery affect the visual outcome after surgery (Giles et al., 2016); (Chak et al., 2006). Management of amblyopia after cataract surgery in children is a big challenge especially in aphakic cases (BenEzra & Cohen, 2000). The minimal cataract surgery age with intra ocular lens implantation is still contraindication. The Infant Aphakia Treatment Study (IATS) concluded that IOL implantation has similar visual outcome to aphakic children with contact lens (Lambert, 2007); (Ma et al., 2003). Cataract surgery in children with left aphakic and secondary IOL implant later has been a trend although controversial.

The rehabilitation of children with amblyopia that causes low vision should be adapted to their need (Courtright et al., 2011). Deprivation amblyopia is the most problem after cataract surgery in children. Therefore it is suggested that congenital cataract must be operated as early as possible because 6 weeks life is the critical period for visual development (Morrison DG, 2017). Amblyopia can also develop after congenital cataract surgery due to anisometropia, strabismus or visual deprivation due to posterior capsule opacification.

Amblyopia rehabilitation should be treated as soon as possible after cataract surgery. It is possible that during general anesthesia after cataract surgery we perform streak retinoscopy to determine the refractive power of the patient's eyes. There are many techniques to rehabilitate the visual acuity after cataract surgery and it should be appropriate to the children's needs.

RESEARCH METHODS

This paper is a case series of low vision in children who had been performed bilateral congenital cataract surgery and received visual rehabilitation in dr Syaiful Anwar Hospital, Malang, Indonesia. The patient's data were obtained from medical records. The data taken were the condition of right eye (OD), left eye (OS) and right and left eye (OU) aphakia (without intraocular lens implantation) or pseudofakia (with intraocular lens implantation), the visual acuity (VA) before and after visual rehabilitation, the VA outcome before and after correction, their timing when they were performed the surgery and the VA correction obtained. The VA correction was given based on the streak retinoscopy assessment. The evaluation of distance VA used visual skill, ivory ball test, lea grating and lea number. The near distance VA was measured using ruler between spectacles to the table while the patient was working on the table.

RESULT AND DISCUSSION

There were 5 cases of low vision in children with history of congenital cataract. They had been performed bilateral cataract surgery. After surgery, they were referred to low vision service in our hospital. Their ages ranged from 20 months – 12 year old. Case 1 was a boy, 7 years old, had OU aphakia, microcornea and nystagmus. The cataract surgery was performed when he was 4 years old and he got spectacle at the same year. The correction for far distance was RLE S+11.00 D and the near distance was RLE S+18.00 D. The far VA was evaluated with visual skill i.e in the way he walk and the near acuity was evaluated while he was drawing. Case 2. A girl, 6 years old, had OU aphakia, microcornea and nystagmus. She underwent cataract surgery when she was 1years old and got spectacle when she was 5 years old. Based on streak retinoscopy the RE correction S+11.00 D and the LE correction S+9.00D. The far distance VA was evaluated

using lea number (fig.1). For near working distance, she got 4M print size at 30 cm, while she was wearing distance spectacle and 4D stand magnifier, she got 2.5 M print size at 30 cm. Case 3. A girl, 12 years old, OU pseudophakia, high myopia and deprivation amblyopia. She underwent the surgery when she was 3 years old and got spectacle when she was 8 years old. The streak retinoscopy was OU S-11.00 D. We evaluated the distance VA using lea number (Fig.2). The near working distance was 2.4 M print size while using 24 D stand magnifier at 30 cm. Case 4. A girl , 20 months old had OU aphakia and microcornea. She underwent surgery when she was 12 months old and got aphakia spectacle at the same time. The streak retinoscopy was RLE S+14.00 D. We evaluated the distance VA using ball test (fig.3). Case 5 A girl, 2 years old, OU aphakia and microcornea. She underwent the surgery when she was 4 months old and got the aphakia spectacle when she was 11 months old. The streak retinoscopy was OU S+16.00 D. We evaluated the distance VA using lea grating (fig.4).

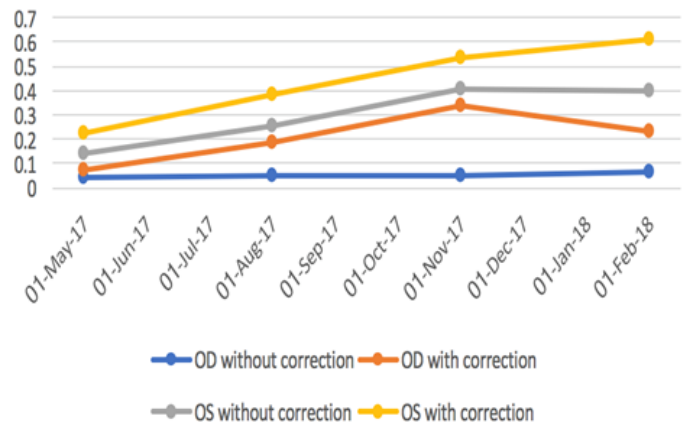


Figure 1. The result of distance VA case 2 using lea number




Figure 2. The result of distance VA case 3 using lea number

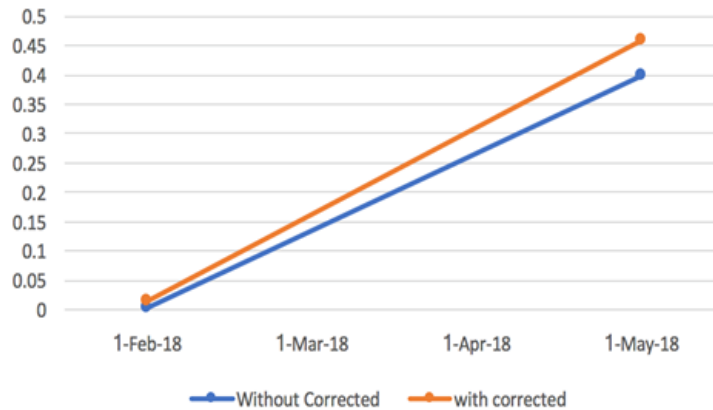

Figure 3. The result of evaluation of distance VA case 4 using ball test

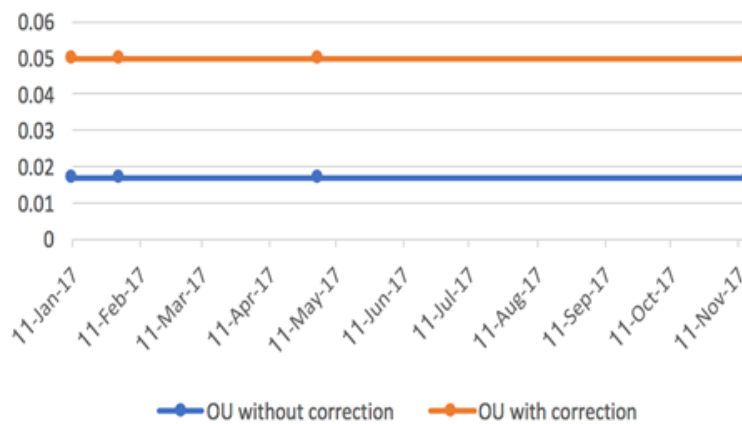


Figure 4. The result of distance VA case 5 using Lea Grating

The success of amblyopia treatment after congenital cataract surgery depends on early detection, timing of cataract surgery and the VA rehabilitation management after cataract surgery. Some ophthalmologists prefer aphakia and do secondary implant because of the patient's condition such as microcornea. During aphakia, the rehabilitation is performed using aphakic glasses or contact lens. If there are other ocular condition, for instance microcornea or supporting capsular bag which are do not accomodate for intraocular lens implantation, the aphakia will be remined as they are but the risk of amblyopia will be greater and the rehabilitation will be more challenging. Visual rehabilitation is to minimize the amblyopia and to optimize the visual function. It is suggested that the rehabilitation must be done as soon as possible after the surgery.

In this case series, we found that the VA outcome was better in case 2 and case 4. Both cases were aphakia because of microcornea. The case 2, underwent cataract surgery at the age of 1 and it was done as soon as possible after detection. But she got the aphakia spectacle for visual rehabilitation at the age of 5. There was an increase of VA development although slower than the case 4. It could be caused by deprivation amblyopia because the time when she got aphakia spectacle was not immediately after cataract surgery. While in the case 4, the patient underwent cataract surgery when she was 12 months old, the surgeon let the eyes aphakic because of microcornea. She got the aphakia spectacle as soon as possible after her cataract surgery. The VA outcome was much better than the other cases. It showed

that as soon as the VA rehabilitation could be possibly performed, it was able to prove the VA although the condition was still aphakia. Some literature stated that successful VA rehabilitation outcome was based on the timing the patient underwent the VA correction, the management or VA rehabilitation and the patient's compliance (Shah et al., 2012); (Trivedi & Wilson, 2005); (Wang & Xiao, 2015).

Whereas for the case number 3, the patient underwent intraocular implantation in both eyes. It should be she could get better VA after surgery. In fact the VA outcome did not improve, this may due to the fact that when she underwent surgery when she was 3 years old she got VA rehabilitation when she was 8 years old. She went over the critical period between the surgery and the VA rehabilitation, thus affecting the VA outcome. Meanwhile, there was also no VA improvement in the case number 4. Although she underwent surgery when she was 4 months old and got VA rehabilitation when she was 11 months old. It could be caused by either the timing of her surgery being over the critical period or the preverbal VA acuity testing technique be reevaluated. It is appropriate to (Chaudhary et al., 2017)Chaudary et al (2017) study stated that early presentation of cataract, nystagmus and poor visual acuity before surgery could influence the VA outcome after surgery.

CONCLUSION

Successful VA rehabilitation in low vision children after congenital cataract surgery depends on the age of the surgery, appropriate technique of rehabilitation, the presence of other congenital ocular abnormalities, and the compliance the patients and the parents compliance of treatment instruction. The VA rehabilitation should be was adjusted to the children's condition and need.

BIBLIOGRAPHY

- BenEzra, D., & Cohen, E. (2000). Cataract surgery in children with chronic uveitis. *Ophthalmology*, 107(7), 1255-1260. [https://doi.org/10.1016/S0161-6420\(00\)00160-3](https://doi.org/10.1016/S0161-6420(00)00160-3).
- Chak, M., Wade, A., & Rahi, J. S. (2006). Long-term visual acuity and its predictors after surgery for congenital cataract: findings of the British congenital cataract study. *Investigative Ophthalmology & Visual Science*, 47(10), 4262-4269. <https://doi.org/10.1167/iovs.05-1160>.
- Chaudhary, S., Lavaju, P., Shrestha, B. G., Shah, S., & Chaudhary, S. K. (2017). Factors affecting the visual outcome of pediatric cataract surgery: a hospital based prospective study in eastern Nepal. *Nepalese Journal of Ophthalmology*, 9(2), 143-148. <https://doi.org/10.3126/nepjoph.v9i2.19258>.
- Courtright, P., Hutchinson, A. K., & Lewallen, S. (2011). Visual impairment in children in middle-and lower-income countries. *Archives of Disease in Childhood*, 96(12), 1129-1134. <https://doi.org/10.1136/archdischild-2011-300093>.
- Giles, K., Christelle, D., Yannick, B., Fricke, O. H., & Wiedemann, P. (2016). Cataract surgery with intraocular lens implantation in children aged 5-15 in

- local anaesthesia: visual outcomes and complications. *Pan African Medical Journal*, 24(1), 1–6. <https://doi.org/10.11604/pamj.2016.24.200.9771>.
- Lambert, S. R. (2007). Treating amblyopia in aphakic and pseudophakic children. *American Orthoptic Journal*, 57(1), 35–40. <https://doi.org/10.3368/aoj.57.1.35>.
- Ma, J. J. K., Morad, Y., Mau, E., Brent, H. P., Barclay, R., & Levin, A. V. (2003). Contact lenses for the treatment of pediatric cataracts. *Ophthalmology*, 110(2), 299–305. [https://doi.org/10.1016/S0161-6420\(02\)01557-9](https://doi.org/10.1016/S0161-6420(02)01557-9).
- Morrison DG. (2017). *Morphology of Congenital Cataract*. Springer E Book Switzerland.
- Shah, M. A., Shah, S. M., Shikhangi, K. A., Upadhyay, P. R., & Bardoloi, G. B. (2012). Factors affecting visual outcome following surgical treatment of cataracts in children. *Open Journal of Ophthalmology*, 2(4), 131–139. <https://doi.org/10.4236/ojoph.2012.24029>.
- Trivedi, R., & Wilson, M. E. (2005). Correction of aphakia: glasses and contact lens. *Pediatric Cataract Surgery: Techniques, Complication and Management*. Lippincott, 306–307.
- Wang, M., & Xiao, W. (2015). Congenital cataract: progress in surgical treatment and postoperative recovery of visual function. *Eye Sci*, 30(1), 38–47. <https://doi.org/10.3969/j.issn.1000-4432.2015.01.009>.

Copyright holders:

Nanda W. Anandita, Lely Retno Wulandari (2023)

First publication right:

AJHS - Asian Journal of Healthy and Science



This article is licensed under a Creative Commons Attribution-ShareAlike 4.0 International