

## **Total *Peperomia pellucida* Extract-Mediated Reversal of Renal Structural Damage Following Cessation of Cigarette Smoke Exposure in Wistar Rats**

**Muhamad Firmansyah Idrus, Johanes Aprilius Falerio Kristijanto, Muzaijadah Retno Arimbi, Mira Kusuma Wardhani, Rini Purbowati, Naufal Syafawi SP, Farida Anggraini Soetedjo\***

Universitas Wijaya Kusuma Surabaya, Indonesia

Email: faridaspp@uwks.ac.id \*

---

### **Abstract**

Cigarette smoking is a recognized risk factor for chronic kidney disease, and experimental data suggest that renal damage may persist even after smoking cessation. *Peperomia pellucida*, a traditional medicinal plant, has documented antioxidant and anti-inflammatory activities and is used empirically for kidney disorders, but its role in reversing smoke-related renal injury is unclear. This study aimed to evaluate whether total *P. pellucida* extract can reverse established renal structural damage following cessation of cigarette smoke exposure in a Wistar rat model. Eighteen healthy male Wistar rats (8–12 weeks, 180–220 g) were randomly assigned to control (CON), cigarette smoke-exposed (CSE), and cigarette smoke-exposed plus *P. pellucida* (CSE+PP400) groups (n=6 each). CSE and CSE+PP400 animals were exposed to cigarette smoke in a whole-body chamber (two cigarettes/rat/day, 4 h/day, 7 days/week) for 4 weeks. Smoke exposure was then discontinued for 4 weeks. During this post-cessation period, CSE+PP400 rats received total *P. pellucida* extract 400 mg/kg/day orally; CON and CSE received vehicle only. At study end, kidneys were processed for hematoxylin–eosin staining and scored using the EGTI (Endothelial, Glomerular, Tubular, Interstitial) system by two blinded pathologists. Data were analyzed using two-way ANOVA. CSE rats showed marked renal injury, with significantly higher EGTI scores in all compartments versus CON. Post-cessation *P. pellucida* treatment significantly reduced endothelial, glomerular, tubular, and interstitial scores compared with untreated CSE rats, although values remained above control levels. No treatment-related mortality was observed. In conclusion, total *P. pellucida* extract administered after smoking cessation partially reverses cigarette smoke-induced renal structural damage in Wistar rats, supporting its potential as an adjunctive nephroprotective option in cigarette smoke-related kidney injury.

**Keywords:** kidney diseases, tobacco smoke pollution, phytotherapy, peperomia

---

## **INTRODUCTION**

Chronic kidney disease (CKD) has emerged as a major non-communicable health burden, affecting more than 800 million individuals worldwide and ranking among the leading causes of death and disability (Hidayangsih et al. 2023; Lan et al. 2023). Beyond traditional drivers such as diabetes and hypertension, lifestyle-related exposures, particularly cigarette smoking, have gained recognition as important, yet modifiable, risk factors for incident CKD and for accelerated loss of renal function (Mallamaci and Tripepi 2024). Epidemiological data consistently link smoking with albuminuria, faster decline in glomerular filtration rate, and poorer renal and cardiovascular outcomes in both the general population and patients with established kidney disease (Lan et al. 2023; Lang and Schiff 2024).

Cigarette smoke contains a complex mixture of reactive oxygen species, nicotine, heavy metals such as cadmium, and pro-inflammatory components that act systemically (Soetedjo et al. 2024a; Soetedjo et al. 2024c). Experimental and clinical studies indicate that chronic exposure promotes oxidative stress, endothelial dysfunction, and low-grade inflammation

within the kidney, leading to podocyte injury, mesangial expansion, tubular degeneration, and interstitial fibrosis (Jiang et al. 2019; Lan et al. 2023). In animal models, cigarette smoke exposure has been shown to reduce renal antioxidant defenses, enhance fibrotic signaling pathways such as transforming growth factor- $\beta$ , and aggravate structural damage in both glomerular and tubular compartments (Liu et al. 2022; Beegam et al. 2024). These structural changes may persist beyond the period of active exposure, suggesting that the kidney retains a form of “injury memory” even after smoking has stopped.

Smoking cessation is therefore a key therapeutic recommendation for patients at risk of, or living with, CKD. Observational cohorts in humans show that discontinuation of smoking reduces the rate of renal function decline and improves long-term renal and cardiovascular prognosis, although full recovery to a nonsmoker phenotype is not always achieved (Lang and Schiffli 2024). Biomarker-based studies also suggest that some smoke-related renal injury is at least partially reversible after cessation, but the speed and completeness of histological repair remain uncertain (Mizdrak et al. 2022; Zhang and Liu 2025). These data highlight a clinically relevant window after cessation in which adjunctive interventions that enhance endogenous repair processes, limit ongoing oxidative and inflammatory damage, and prevent maladaptive fibrosis could meaningfully improve renal outcomes.

*Peperomia pellucida* is a small herbaceous plant widely distributed in tropical regions and traditionally used in Indonesia, the Philippines, Brazil, and other countries for the treatment of gout, inflammatory conditions, pain, and kidney-related complaints (Alves et al. 2019; Gomes et al. 2022). Phytochemical analyses show that the plant is rich in phenolic acids, flavonoids, and other bioactive constituents with documented antioxidant and anti-inflammatory activities in vitro and in vivo (Amirah et al. 2020; Soetedjo et al. 2024b). Extracts of *P. pellucida* have demonstrated analgesic, anti-inflammatory, antidiabetic, and renally relevant pharmacological properties, including modulation of oxidative stress markers and inflammatory mediators in experimental models (Aska et al. 2025; Kristijanto et al. 2025). These features make the plant an appealing candidate for organ-protective strategies in conditions where redox imbalance and inflammation drive progressive tissue damage.

Emerging preclinical work has begun to explore the nephroprotective potential of *P. pellucida* in the context of tobacco smoke exposure, suggesting that administration of the extract can ameliorate smoke-induced histopathological abnormalities in rat kidneys. However, most available studies focus on concurrent treatment during active exposure and do not specifically address the therapeutically relevant scenario in which kidney injury has already been established and smoking has been discontinued. In this post-cessation setting, the question is not merely whether damage can be prevented, but whether structural lesions that have already developed can be reversed or remodeled towards a more normal architecture.

Against this background, there is a clear knowledge gap regarding the capacity of total *P. pellucida* extract to promote renal structural recovery once cigarette smoke exposure has ceased. To address this gap, the present study employed a Wistar rat model of chronic cigarette smoke exposure followed by a cessation period, during which animals received total *P. pellucida* extract. We specifically aimed to determine whether this intervention reverses established histopathological damage in renal tissue. By focusing on the post-cessation phase, this work seeks to emulate a clinically meaningful scenario and to evaluate *P. pellucida* as a

potential adjunctive nephroprotective therapy for individuals with smoke-related kidney injury who have successfully stopped smoking.

## RESEARCH METHODS

### Plant material collection and preparation

Fresh leaves and stems of *P. pellucida* were collected from Surabaya, Indonesia during April 2025. The plant material was taxonomically identified and authenticated by an experienced botanist from Herbal Materia Medica Laboratory, Batu, East Java, Indonesia, and a voucher specimen (No. 000.9.3/3693/102.20/2025) was prepared and deposited in the same institution for future reference.

After authentication, the leaves and stems were washed thoroughly under running tap water to remove soil and debris, followed by a final rinse with distilled water. The clean material was cut into small pieces and dried in a hot-air oven at 40–50 °C until a constant weight was achieved, corresponding to a moisture content of less than 10%. The dried material was then ground into a fine powder (simplicia) using a mechanical grinder and stored in an airtight container until extraction.

The powdered sample was extracted by maceration with 96% ethanol for three days at room temperature with occasional stirring. At the end of the maceration period, the mixture was filtered to obtain the ethanolic filtrate. The combined filtrate was concentrated under reduced pressure using a rotary evaporator at 50 °C and further evaporated on a water bath to yield a thick, dried crude extract. The total *P. pellucida* extract was transferred to a sealed, light-protected container and stored at 5 °C until further use (Kristijanto et al. 2025).

### Experimental design and animals

This study used a true experimental design with a post-test-only control group. Eighteen clinically healthy male Wistar rats (*Rattus norvegicus*), 8–12 weeks of age and weighing 180–220 g at baseline, were included. Before the start of the interventions, all animals were acclimatized for seven days in the animal facility under standard laboratory conditions: temperature 22–25 °C, relative humidity 50–60%, and a 12 h light/12 h dark cycle. Rats were housed in standard polypropylene cages with clean bedding, received a commercial rat chow, and had free access to drinking water throughout the experiment. Health status and general behavior were monitored daily. After acclimatization, the animals were randomly allocated into three groups (n = 6 per group):

1. Control group (CON) – received standard feed without cigarette smoke exposure or extract administration.
2. Cigarette smoke-exposed group (CSE) – received standard feed and were exposed to cigarette smoke for four weeks.
3. Cigarette smoke-exposed and *P. pellucida*-treated group (CSE+PP400) – underwent the same cigarette smoke exposure protocol as CSE, followed by administration of *P. pellucida* extract at 400 mg/kg body weight after cessation.

Cigarette smoke exposure was carried out in a closed exposure chamber for four consecutive weeks. Rats in CSE and CSE+PP400 were exposed to the smoke of two cigarettes per rat per day, for a total of 4 hours daily, seven days per week. The cigarettes were burned outside the cages and the smoke was introduced into the chamber to simulate whole-body exposure. The control group was handled in parallel but was not exposed to cigarette smoke.

At the end of the four-week exposure period, cigarette smoke was discontinued in both CSE and CSE+PP400. Rats in CSE continued to receive only standard feed and water for an additional four weeks (cessation period). Rats in CSE+PP400 received total *P. pellucida* extract at a dose of 400 mg/kg body weight by oral gavage once daily for four weeks following smoke cessation, in addition to standard feed. Body weight was recorded weekly, and the extract dose was adjusted accordingly to maintain the target mg/kg dosing (Soetedjo et al. 2024b).

All experimental procedures were conducted in accordance with internationally accepted guidelines for the care and use of laboratory animals and were approved by Research Ethics Committee of the Faculty of Medicine, Universitas Wijaya Kusuma Surabaya, Surabaya, Indonesia (Approval No.: 56/SLE/FK/UWKS/2025).

### Histopathological preparation and examination

At the end of the experimental period, all rats were fasted for 12 hours with free access to water and then euthanized under deep anesthesia using ketamine (75 mg/kg, intraperitoneal) and xylazine (10 mg/kg, intraperitoneal). Both kidneys were immediately removed through a midline abdominal incision, gently trimmed of adherent tissue, and rinsed in 0.9% NaCl solution to remove excess blood. The organs were then immersed in 10% neutral-buffered formalin (NBF) for at least 24 hours for fixation.

Fixed kidney samples were processed using standard histological procedures. Briefly, tissues were dehydrated through a graded series of ethanol, cleared in xylene, and embedded in paraffin. Paraffin blocks were sectioned at a thickness of 4 µm using a rotary microtome. The sections were mounted on glass slides, dried, and subsequently stained with hematoxylin–eosin (H&E) to allow evaluation of general renal morphology.

Histopathological examination was performed under a light microscope (Olympus BX43, Olympus Corporation, Tokyo, Japan) to assess structural alterations in the glomerular, tubular, endothelial, and interstitial compartments. Renal injury was semi-quantitatively evaluated using the EGTI (Endothelial, Glomerular, Tubular, Interstitial; Table 1) scoring system, which grades the extent of tissue damage from normal architecture to severe degeneration and necrosis (Perera et al. 2020). For each kidney, EGTI scores were assigned based on observations in several non-overlapping representative fields at 200× and 400× magnification, and expressed as an individual EGTI score, with higher values indicating more severe histopathological injury.

**Table 1: The EGTI scoring system.**

Tissue	Lesions Criteria	Score
Endothelium	No damage	0
	Endothelial swelling	1
	Endothelial disruption	2
	Loss of endothelium	3
Glomerulus	No damage	0
	Thickening of Bowman's Capsule	1
	Glomerular retraction	2
	Glomerular fibrosis	3
Tubules	No damage	0
	Loss of Brush Border < 25% of tubular cells at basement membrane	1
	Loss of Brush Border > 25% of tubular cells, basement membrane thickening	2
	Inflammation, necrosis ≤ 60% of tubular cells	3

	Necrosis > 60% of tubular cells	4
	No damage	0
	Inflammation or hemorrhage < 25% of tissue	1
<b>Interstitial</b>	Necrosis < 25% of tissue	2
	Necrosis 25-60% of tissue	3
	Necrosis > 60% of tissue	4

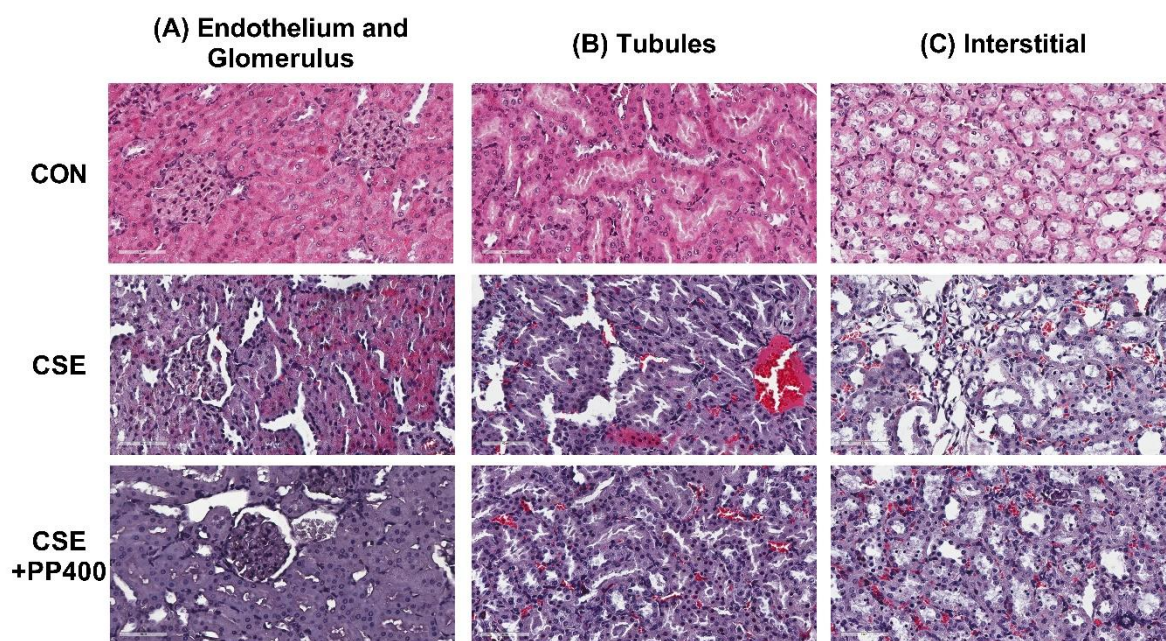
### Statistical analysis

Histopathological data (EGTI scores) were summarized as mean  $\pm$  standard deviation (SD). To evaluate the effects of cigarette smoke exposure and *P. pellucida* treatment on renal injury, we used two-way analysis of variance (two-way ANOVA), with treatment group (CON, CSE, CSE+PP400) and renal compartment (endothelial, glomerular, tubular, interstitial) specified as fixed factors. When a significant main effect or interaction was detected, pairwise comparisons between groups were carried out using an appropriate post hoc test to identify specific differences. All tests were two-tailed, and a p-value < 0.05 was considered statistically significant. Statistical analyses were performed using GraphPad Prism version 9.0 (GraphPad Software, San Diego, CA, USA).

## RESULTS AND DISCUSSION

All animals completed the experimental protocol without procedure-related mortality. Throughout the study, rats in all groups remained active, with normal grooming behavior and food intake. There were no obvious signs of respiratory distress or severe systemic illness during the exposure or cessation periods.

Histological examination of kidneys from the control (CON) group revealed preserved renal architecture with normal-appearing glomeruli, intact Bowman's capsules, and regular tubular epithelial cells. The interstitium was thin and devoid of inflammatory infiltrates, and the vascular endothelium appeared unremarkable (Figure 1).



**Figure 1.** Representative hematoxylin–eosin–stained kidney sections from control rats (CON), cigarette smoke-exposed rats (CSE), and cigarette smoke-exposed rats treated with total *Peperomia pellucida* extract after cessation (CSE+PP400). (A) Endothelium and glomerulus: CON kidneys show normal

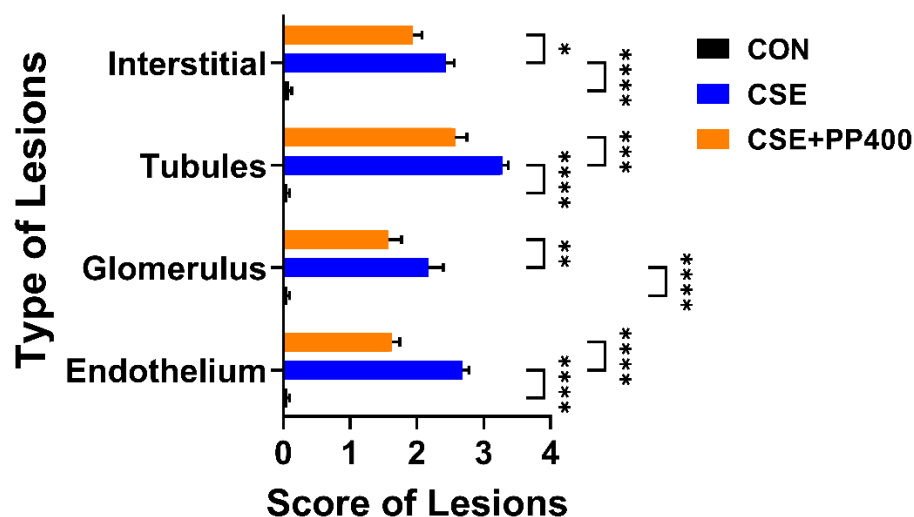


glomerular architecture with preserved capillary loops and intact Bowman's spaces. CSE kidneys display glomerular distortion with mesangial expansion, capillary congestion, and endothelial swelling. In CSE+PP400 rats, glomerular morphology is partly restored, with less mesangial expansion and reduced congestion. (B) Tubules: CON kidneys exhibit regular tubular epithelial cells with well-preserved structure. CSE kidneys show tubular epithelial swelling, cytoplasmic vacuolization, luminal dilatation, and focal necrosis. CSE+PP400 kidneys demonstrate attenuated tubular damage, with improved epithelial integrity and fewer degenerative changes. (C) Interstitium: CON kidneys present a thin interstitium without inflammatory infiltrates. CSE kidneys reveal interstitial expansion with inflammatory cell infiltration and early fibrotic changes, whereas CSE+PP400 kidneys show reduced interstitial thickening and inflammatory infiltration, indicating partial reversal of cigarette smoke-induced injury. Scale bar = 60  $\mu$ m.

In contrast, kidneys from rats exposed to cigarette smoke without treatment (CSE group) showed clear evidence of structural injury (Figure 1). Glomeruli frequently exhibited mesangial expansion, segmental capillary congestion, and mild to moderate distortion of the capillary tuft. Tubular changes included epithelial cell swelling, loss of brush border, cytoplasmic vacuolization, and focal tubular dilatation. Areas of tubular degeneration and necrosis were observed in some fields. The interstitium showed thickening with scattered inflammatory cell infiltrates and early fibrotic changes, while small blood vessels demonstrated endothelial swelling and narrowing of the vascular lumen. Taken together, these findings are consistent with cigarette smoke-induced glomerular, tubular, endothelial, and interstitial injury.

Administration of total *P. pellucida* extract after smoke cessation (CSE+PP400 group) was associated with a noticeable improvement in renal histology compared with the CSE group (Figure 1). Glomerular morphology appeared closer to normal, with reduced mesangial expansion and less pronounced capillary congestion. Tubular epithelial cells showed better preservation of cellular integrity, with fewer areas of overt degeneration or necrosis. Interstitial thickening and inflammatory infiltrates were diminished, and vascular endothelial changes were less prominent. Although occasional mild lesions were still observed, the overall architectural pattern suggested partial reversal of smoke-induced damage during the post-cessation treatment period.

These qualitative observations were supported by semi-quantitative analysis using the EGTI scoring system. The individual EGTI score was lowest in the CON group, indicating largely preserved renal structure, and highest in the CSE group, reflecting extensive endothelial, glomerular, tubular, and interstitial injury. Rats in the CSE+PP400 group showed intermediate scores, consistent with histological evidence of recovery (Figure 2).



**Figure 2.** Semi-quantitative EGTI subscores for endothelial, glomerular, tubular, and interstitial lesions in control rats (CON), cigarette smoke–exposed rats (CSE), and cigarette smoke–exposed rats treated with total *Peperomia pellucida* extract after cessation (CSE+PP400). Bars represent mean  $\pm$  SD ( $n = 6$  per group). Cigarette smoke exposure markedly increased all lesion scores compared with controls, whereas post-cessation *P. pellucida* treatment significantly reduced endothelial, glomerular, tubular, and interstitial scores relative to untreated CSE rats, although values remained above those of CON. Statistical analysis was performed using two-way ANOVA followed by post hoc testing. \* $p < 0.05$ , \*\* $p < 0.01$ , \*\*\* $p < 0.001$ , \*\*\*\* $p < 0.0001$ .

Statistical analysis confirmed significant differences in individual EGTI subscores among the three groups ( $p < 0.05$ – $0.0001$ , two-way ANOVA). For all lesion types, endothelial, glomerular, tubular, and interstitial, the CSE group showed markedly higher scores than CON, indicating extensive cigarette smoke–induced renal injury. Treatment with total *P. pellucida* extract after smoke cessation (CSE+PP400) significantly lowered lesion scores compared with untreated CSE rats for each compartment, demonstrating a consistent attenuation of smoke-related damage. However, EGTI subscores in the CSE+PP400 group remained above those of controls, suggesting that the four-week post-cessation treatment achieved substantial but incomplete reversal of established renal lesions.

Analysis of lesion-specific EGTI subscores showed a coherent pattern across all renal compartments. For endothelial lesions, the CSE group had the highest scores, which were significantly elevated compared with CON ( $p < 0.0001$ ), whereas post-cessation treatment with total *P. pellucida* extract (CSE+PP400) significantly reduced endothelial scores relative to CSE ( $p < 0.0001$ ), although values in CSE+PP400 remained higher than in CON. A similar trend was observed for glomerular damage: CSE rats exhibited significantly higher glomerular scores than CON ( $p < 0.0001$ ), CSE+PP400 animals showed significantly lower scores than CSE ( $p < 0.01$ ), yet these scores did not fully return to control levels. Tubular lesions were the most prominent, with CSE rats demonstrating markedly increased tubular scores compared with CON ( $p < 0.0001$ ); *P. pellucida* treatment significantly attenuated tubular injury (CSE+PP400 vs CSE,  $p < 0.001$ ), but tubular scores in CSE+PP400 remained higher than in CON. Interstitial scores followed the same pattern: CSE rats had significantly greater interstitial damage than controls ( $p < 0.0001$ ), *P. pellucida* treatment significantly reduced these scores compared with CSE ( $p < 0.05$ ), yet values in CSE+PP400 were still above those of CON. Together, these

findings indicate that total *P. pellucida* extract consistently mitigates endothelial, glomerular, tubular, and interstitial injury after smoking cessation, achieving substantial, but not complete, reversal of established renal lesions.

This experimental study shows that cigarette smoke exposure induces multifocal renal injury in Wistar rats and that administration of total *P. pellucida* extract during the post-cessation period can significantly attenuate, though not completely normalize, these structural changes. Using the EGTI scoring system, we observed marked increases in endothelial, glomerular, tubular, and interstitial lesion scores in smoke-exposed animals compared with controls, while rats receiving *P. pellucida* after cessation exhibited consistently lower scores in all compartments. These data support the idea that renal damage related to cigarette smoke is at least partially reversible and that phytotherapeutic intervention may facilitate tissue recovery once exposure has stopped.

Our findings are in line with epidemiological evidence that smoking is an important, modifiable risk factor for CKD. Large cohort studies and meta-analyses have shown that current smokers have a higher risk of incident CKD, albuminuria, and kidney failure than never-smokers, independent of traditional risk factors such as diabetes and hypertension (Moraes et al. 2021; Hidayangsih et al. 2023; Lan et al. 2023; Lang and Schiff 2024; Mallamaci and Tripepi 2024). More recent population-based analyses also suggest that CKD risk remains elevated for years after quitting, although long-term cessation is associated with a gradual risk reduction compared with continuing smokers. These observations imply that tobacco-related renal injury has a degree of persistence, but is not entirely fixed. Our model, in which histopathology was evaluated after a defined cessation period, was designed to mimic this clinical reality. The persistence of high EGTI scores in the CSE group despite four weeks without smoke supports the concept of a “residual injury” phenotype, while the lower scores in the *P. pellucida*-treated group indicate that active repair can be pharmacologically enhanced.

Mechanistically, the pattern of injury we observed, combining glomerular distortion, tubular degeneration, endothelial swelling, and interstitial thickening, is consistent with previous experimental data on cigarette smoke-induced renal damage (Jiang et al. 2019; Moraes et al. 2021). Cigarette smoke exposure in rodents has been shown to increase oxidative stress, impair antioxidant defenses, promote inflammatory signaling, and accelerate fibrotic remodeling in the kidney. Such changes provide a plausible pathophysiological link between smoking and the higher rates of albuminuria and eGFR decline reported in human cohorts. The fact that histological damage in our CSE group remained pronounced after a smoke-free interval underscores the limited capacity of spontaneous repair once structural injury is established, and highlights the need for adjunctive strategies alongside smoking cessation.

We used the EGTI scoring system to capture lesion severity across four key renal compartments: endothelium, glomeruli, tubules, and interstitium. This composite tool was originally developed and validated in rat models of ischemia-reperfusion injury as a reproducible method for semi-quantitative histological assessment (Perera et al. 2020). Its application in our study allowed us to demonstrate that cigarette smoke does not target a single nephron segment, but rather produces a diffuse pattern of injury, and that *P. pellucida*-mediated protection involves parallel improvements in microvascular, glomerular, and tubulointerstitial compartments. The concordant reduction of E, G, T, and I scores in the



CSE+PP400 group suggests a global amelioration of renal damage rather than a localized effect limited to one structure.

*Peperomia pellucida* is widely used in traditional medicine for kidney ailments, hypertension, and inflammatory conditions, and several experimental studies have begun to substantiate these indications. Phytochemical analyses indicate that the plant is rich in phenolic compounds, flavonoids, and other secondary metabolites with antioxidant and anti-inflammatory properties (Gomes et al. 2022; Tuan and Men 2024; Teodhora et al. 2025). In various models, *P. pellucida* extracts have been shown to scavenge reactive oxygen species, reduce lipid peroxidation, enhance endogenous antioxidant defenses, and down-regulate pro-inflammatory cytokines such as TNF- $\alpha$  and IL-1 $\beta$  (Pertiwi et al. 2022; Aska et al. 2025; Kristijanto et al. 2025). Renal-specific data are still limited but broadly supportive. In alloxan-induced diabetic mice, *P. pellucida* extract improved glomerular and tubular histology and attenuated renal damage, likely via its antidiabetic and antioxidant actions (Hamzah et al. 2012; Saryono et al. 2020).

Our findings extend this literature by showing that total *P. pellucida* extract not only prevents or limits damage during exposure, as several herbal interventions do, but can also facilitate partial reversal of established lesions when given after the insult has stopped. Although we did not measure molecular markers in the present study, it is reasonable to hypothesize that the reduced EGTI scores in the CSE+PP400 group reflect a combination of antioxidant and anti-inflammatory effects, along with improved microvascular function. Cigarette smoke introduces a heavy burden of reactive oxygen species and toxicants such as cadmium and nicotine, which can damage endothelial cells, mesangial cells, and tubular epithelium (Seo et al. 2023). By dampening oxidative stress and inflammatory signaling, *P. pellucida* may create a more favorable milieu for cellular repair, limit progressive fibrosis, and preserve capillary integrity, thereby translating into the lower histopathological scores we observed. Additional support for this paradigm comes from studies of other antioxidant-rich plant preparations, which have been shown to ameliorate kidney histopathology in rats exposed to cigarette smoke or similar oxidant stresses (Ibrahim et al. 2016).

From a translational perspective, our data are consistent with the notion that smoking cessation alone, although indispensable, may not be sufficient to fully reverse smoke-related kidney damage, at least in the short to medium term (Moraes et al. 2021; Lang and Schiff 2024). Clinical cohorts indicate that former smokers retain a higher risk of CKD and albuminuria than never-smokers for many years, even though risk declines with longer cessation duration (Fu et al. 2022). The partial recovery observed in the CSE+PP400 group suggests that adjunctive nephroprotective therapies might accelerate structural repair during this vulnerable post-cessation window. In this context, a standardized *P. pellucida* preparation, if eventually proven effective and safe in humans, could be envisioned as a complementary strategy for individuals with smoke-related renal injury who have successfully quit smoking. It is important to emphasize that such phytotherapy should be viewed as an adjunct, not an alternative, to comprehensive risk factor control, including smoking cessation, blood pressure management, and glycemic control.

Several limitations of the present work should be acknowledged. First, we relied primarily on histopathological endpoints and did not include functional parameters such as serum creatinine, blood urea nitrogen, or albuminuria, nor did we quantify oxidative stress,

inflammatory, or fibrotic biomarkers in renal tissue. As a result, we cannot directly link structural improvement to functional recovery. Second, only one dose of *P. pellucida* extract and a single four-week post-cessation treatment period were evaluated. Different dosing regimens, extract standardization based on key phytoconstituents, and longer follow-up may yield greater or more sustained reversal of injury. Third, we studied only male Wistar rats, and sex-specific or strain-specific differences in susceptibility and response cannot be excluded. Finally, as with all plant extracts, batch-to-batch variability and the presence of multiple active components complicate mechanistic attribution.

Future studies should therefore incorporate comprehensive functional assessment, redox and inflammatory profiling, and analysis of fibrotic signaling pathways to better define how *P. pellucida* modulates the trajectory of smoke-induced kidney disease. Dose–response experiments, comparison of different extract fractions, and longer post-cessation observation periods would also help clarify the extent to which renal damage can be reversed. It would be particularly informative to integrate EGTI scoring with molecular readouts and imaging-based assessments of microvascular integrity, thereby linking microscopic structural changes to broader kidney function.

## CONCLUSION

In summary, this study demonstrates that chronic cigarette smoke exposure produces widespread endothelial, glomerular, tubular, and interstitial injury in rat kidneys, and that total *Peperomia pellucida* extract administered after smoking cessation can significantly reduce the severity of these lesions. Although histopathology did not return fully to control levels, the consistent improvement across all EGTI domains indicates that *P. pellucida* facilitates partial reversal of established renal structural damage. These findings add to the growing body of evidence supporting *P. pellucida* as a promising nephroprotective phytotherapeutic and provide a rationale for further mechanistic and translational research in the context of smoke-related kidney injury.

## REFERENCES

- Alves, N.S.F., Setzer, W.N. and da Silva, J.K.R. 2019. The chemistry and biological activities of *Peperomia pellucida* (Piperaceae): A critical review. *Journal of Ethnopharmacology* 232, pp. 90–102. doi: 10.1016/j.jep.2018.12.021.
- Amirah, S., Zain, H.H.M., Husni, I., Kassim, N.K. and Amin, I. 2020. In vitro Antioxidant Capacity of *Peperomia pellucida* (L.) Kunth Plant from two different locations in Malaysia using different Solvents Extraction. *Research Journal of Pharmacy and Technology* 13(4), p. 1767. doi: 10.5958/0974-360X.2020.00319.4.
- Aska, A.A. Al, Soetedjo, F.A. and Kristijanto, J.A.F. 2025. Efek Protektif Ekstrak *Peperomia pellucida* terhadap Fibrosis Jantung yang Diinduksi Paparan Asap Rokok: Suatu Studi Pre-Klinis. *Jurnal Sehat Indonesia (JUSINDO)* 7(2), pp. 586–594. doi: 10.59141/jsi.v7i2.299.
- Beegam, S., Al-Salam, S., Zaaba, N.E., Elzaki, O., Ali, B.H. and Nemmar, A. 2024. Effects of Waterpipe Smoke Exposure on Experimentally Induced Chronic Kidney Disease in

- Mice. International Journal of Molecular Sciences 25(1), p. 585. doi: 10.3390/ijms25010585.
- Fu, Y.-C., Xu, Z.-L., Zhao, M.-Y. and Xu, K. 2022. The Association Between Smoking and Renal Function in People Over 20 Years Old. *Frontiers in Medicine* 9. doi: 10.3389/fmed.2022.870278.
- Gomes, P.W.P. et al. 2022. Chemical Composition of Leaves, Stem, and Roots of *Peperomia pellucida* (L.) Kunth. *Molecules* 27(6), p. 1847. doi: 10.3390/molecules27061847.
- Hamzah, R.U., Odetola, A.A., Erukainure, O.L. and Oyagbemi, A.A. 2012. *Peperomia pellucida* in diets modulates hyperglycemia, oxidative stress and dyslipidemia in diabetic rats. *Journal of Acute Disease* 1(2), pp. 135–140. doi: 10.1016/S2221-6189(13)60031-1.
- Hidayangsih, P.S., Tjandrarini, D.H., Sukoco, N.E.W., Sitorus, N., Dharmayanti, I. and Ahmadi, F. 2023. Chronic kidney disease in Indonesia: evidence from a national health survey. *Osong Public Health and Research Perspectives* 14(1), pp. 23–30. doi: 10.24171/j.phrp.2022.0290.
- Ibrahim, Z.S., Alkafafy MOHAMED ELSAYED, Ahmed, M.M. and Soliman, M.M. 2016. Renoprotective effect of curcumin against the combined oxidative stress of diabetes and nicotine in rats. *Molecular Medicine Reports* 13(4), pp. 3017–3026. doi: 10.3892/mmr.2016.4922.
- Jiang, S., Quan, D. Van, Sung, J.H., Lee, M.-Y. and Ha, H. 2019. Cigarette smoke inhalation aggravates diabetic kidney injury in rats. *Toxicology Research* 8(6), pp. 964–971. doi: 10.1039/c9tx00201d.
- Kristijanto, J.A.F., Zahiroh, V.N., Triadi, A., Khamidah, N. and Soetedjo, F.A. 2025. Protective Effects of *Peperomia pellucida* Extract Against Secondhand Smoke-Induced Pulmonary Fibrosis via Antioxidant and Anti-inflammatory Pathways. *Tropical Journal of Natural Product Research* 9(9). doi: 10.26538/tjnpr/v9i9.50.
- Lan, R. et al. 2023. Secondhand smoke, genetic susceptibility, and incident chronic kidney disease in never smokers: A prospective study of a selected population from the UK Biobank. *Tobacco Induced Diseases* 21(May), pp. 1–9. doi: 10.18332/tid/162607.
- Lang, S.M. and Schiffl, H. 2024. Smoking status, cadmium, and chronic kidney disease. *Renal Replacement Therapy* 10(1), p. 17. doi: 10.1186/s41100-024-00533-3.
- Liu, W.-C., Chuang, H.-C., Chou, C.-L., Lee, Y.-H., Chiu, Y.-J., Wang, Y.-L. and Chiu, H.-W. 2022. Cigarette Smoke Exposure Increases Glucose-6-phosphate Dehydrogenase, Autophagy, Fibrosis, and Senescence in Kidney Cells In Vitro and In Vivo. *Oxidative Medicine and Cellular Longevity* 2022, pp. 1–16. doi: 10.1155/2022/5696686.
- Mallamaci, F. and Tripepi, G. 2024. Risk Factors of Chronic Kidney Disease Progression: Between Old and New Concepts. *Journal of Clinical Medicine* 13(3), p. 678. doi: 10.3390/jcm13030678.
- Mizdrak, M., Kumrić, M., Kurir, T.T. and Božić, J. 2022. Emerging Biomarkers for Early Detection of Chronic Kidney Disease. *Journal of Personalized Medicine* 12(4), p. 548. doi: 10.3390/jpm12040548.
- Moraes, C.A. de, Breda-Stella, M. and Carvalho, C.A.F. 2021. Morphofunctional study on the effects of passive smoking in kidneys of rats. *Einstein (São Paulo)* 19. doi: 10.31744/einstein\_journal/2021AO6000.

- Perera, T., Ranasinghe, S., Alles, N. and Waduge, R. 2020. Experimental rat model for acute tubular injury induced by high water hardness and high water fluoride: efficacy of primary preventive intervention by distilled water administration. *BMC Nephrology* 21(1), p. 103. doi: 10.1186/s12882-020-01763-3.
- Pertiwi, R., Samudra, A.G., Wati, N.K., Hanuun, A., Yudha S, S., Notriawan, D. and Wibowo, R.H. 2022. Gastroprotective activities of *Peperomia pellucida* L. and *Pachyrhizus erosus* L. extracts combination on ethanol-induced rats. *Inflammopharmacology* 30(6), pp. 2139–2144. doi: 10.1007/s10787-022-00982-4.
- Saryono, S., Hernayanti, H. and Proverawati, A. 2020. Anti-toxicity test of *Peperomia pellucida* steeping on liver function in diabetic-induced rat. *Molekul* 15(2), p. 97. doi: 10.20884/1.jm.2020.15.2.586.
- Seo, Y.-S., Park, J.-M., Kim, J.-H. and Lee, M.-Y. 2023. Cigarette Smoke-Induced Reactive Oxygen Species Formation: A Concise Review. *Antioxidants* 12(9), p. 1732. doi: 10.3390/antiox12091732.
- Soetedjo, F.A., Falerio, J.A. and Sunarjo. 2024a. Suplementasi Gandum Sebagai Upaya Atenuasi Inflamasi Sistemik Pada Serum Mencit Pasca Penghentian Pajanan Asap Rokok. In: *Prosiding Seminar Nasional COSMIC Kedokteran*. pp. 151–156. Available at: <https://prosidingcosmic.fk.uwks.ac.id/index.php/cosmic/article/view/39> [Accessed: 22 November 2025].
- Soetedjo, F.A., Kristijanto, J.A., Agusaputra, H. and Kusumaningtyas, M.J. 2024b. *Peperomia pellucida* Extract Ameliorates Secondhand Smoke Exposure-Induced Lung Fibrogenesis via Regulation of Matrix Metalloproteinase, Inflammatory, and Fibrotic Cytokines: A Pre-Clinical Study. *Pharmaceutical Sciences Asia Pharm Sci Asia* 51(3), pp. 223–232. doi: 10.29090/psa.2024.03.24.AP0565.
- Soetedjo, F.A., Kristijanto, J.A. and Khamidah, N. 2024c. Attenuation of Cigarette-Smoke-Induced Oxidative Stress By Oat Diet. *Indonesian Journal for Health Sciences* 8(1), pp. 91–96. Available at: <https://journal.umpo.ac.id/index.php/IJHS/article/view/6599> [Accessed: 23 August 2024].
- Teodhora, -, Hendriani, R., Sumiwi, S. and Levita, J. 2025. *Peperomia pellucida* (L.) Kunth: A Decade of Ethnopharmacological, Phytochemical, and Pharmacological Insights (2014–2025). *Journal of Experimental Pharmacology Volume 17*, pp. 417–454. doi: 10.2147/JEP.S532898.
- Tuan, C.T. and Men, T.T. 2024. *Peperomia pellucida*'s Ingredients, Antioxidant Properties, and Safe Usage as Food and Herbal Medicine. *Journal of Microbiology and Biotechnology* 34(11), pp. 2321–2330. doi: 10.4014/jmb.2406.06025.
- Zhang, P.L. and Liu, M.-L. 2025. From acute tubular injury to tubular repair and chronic kidney diseases – KIM-1 as a promising biomarker for predicting renal tubular pathology. *Current Research in Physiology* 8, p. 100152. doi: 10.1016/j.crphys.2025.100152.

**Copyright holders:**

**Muhamad Firmansyah Idrus, Johanes Aprilius Falerio Kristijanto, Muzaijadah Retno Arimbi, Mira Kusuma Wardhani, Rini Purbowati, Naufal Syafawi SP, Farida Anggraini Soetedjo\* (2026)**

**First publication right:**

**AJHS - Asian Journal of Healthy and Science**



**This article is licensed under a Creative Commons Attribution-ShareAlike 4.0 International**